

How Physical Therapy Can Help You Come Back After a Low Back Injury

At one time or another, lower back pain will affect most people. This pain can be due to poor posture, incorrect movements, lifting methods, stress, illness and/or injury. Maintaining a **safe posture** and participating in **proper exercise** can strengthen the lower back and prevent injury. But when the lower back has been injured, rehabilitation can restore functionality and help prevent further incidents.

Three main muscle groups control the back:

- **Extensors**—this group is employed during lifting and extending
- **Flexors**—the flexors provide support for the spine from the abdominal area, and also control the lumbar or lower area of the spine
- **Obliques and rotators**—these side muscles are responsible for posture and stabilizing the spine while standing

After an injury we can evaluate which muscles need rehabilitation and which exercises would be most applicable and beneficial. Research has shown that a combination of stretching exercises and strengthening methods are most effective post-injury. When pain prevents movement, weakness sets in and rehabilitation becomes essential in building the muscle to its pre-injury state and strengthening it to avoid future injury.

We have learned that the deep rotational muscles are especially difficult to rehabilitate and often require targeted exercises, not only those that focus on the lower back—the discs, muscles, ligaments and tendons—but also the abdominal muscles, as they play an important role in supporting the spine.

Exercises that can help:

- Abdominal strengthening
- Yoga
- Water therapy
- Utilizing medicine balls or weights



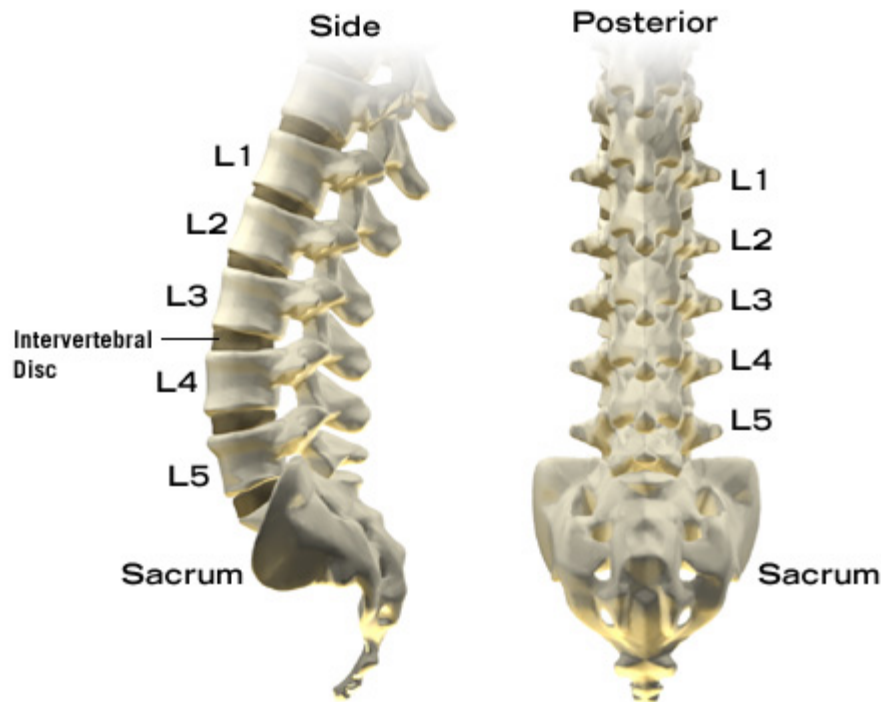
The deeper back muscles are frequently used in back extension through raising or arching the spine. A helpful exercise is the **superman**, whereby you lie stomach-down on a surface, raising your legs and arms as if you were flying. Performing **aerobic exercises** such as walking, swimming and biking, along with targeted strengthening and stretching exercises, can regularly help you decrease recurrence of back pain—and improve your function as you resume your favorite activities.

Stay tuned to read about the role of BODYWORK in recovering from Low Back injury! Or go to www.wholisticphysicaltherapy.com/articles

Anatomy of Low Back Pain

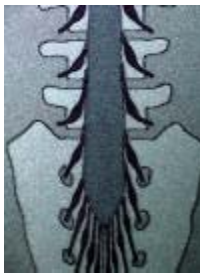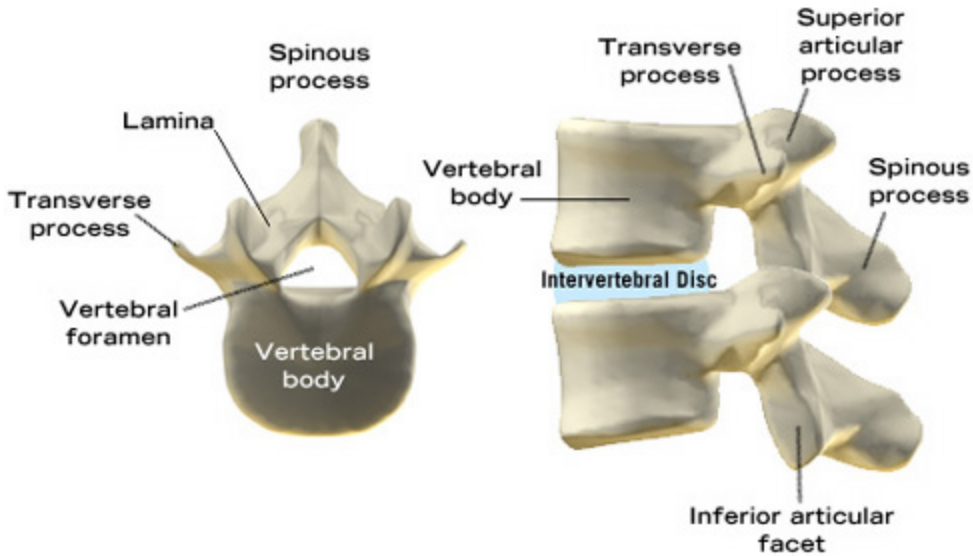
The lumbar spine consists of five lumbar vertebral bodies. These sit on top of the sacrum, which in turn is above the coccyx (tailbone). The lumbar spine

supports the thoracic spine (which has twelve vertebral levels), and this in turn supports the cervical spine (neck), which has seven levels. Finally, the cervical spine supports the head. It is therefore clear that the lumbar spine supports most of the weight of the body. Its vertebral bodies are the largest of the spine, because of the large amount of weight they must bear.

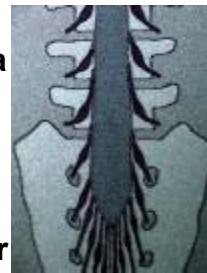

In the bottom left view the vertebral body is seen as an oval segment of bone. This will support the bulk of the weight of the body. In between the vertebral bodies lie the intervertebral disks, which act as shock absorbers when healthy, but when ruptured into the spinal canal, can cause pressure on the nerve roots. From the vertebral body arise the pedicles and then the lamina. These form the covering, and therefore the protection of the spinal nerves. This triangular space is known as the spinal canal. The spinous process is seen protruding from the junction of the two laminae, and is often palpable of thin people. These spinous processes are the ridges or bumps one feels along the back of the spine. Transverse processes are seen projecting from the junction of the pedicles and lamina. Facet joints are joints by which one vertebral body segment is connected with the next segment.

In the bottom right view one can gain an appreciation for the complexity of the vertebral body and its attachments.

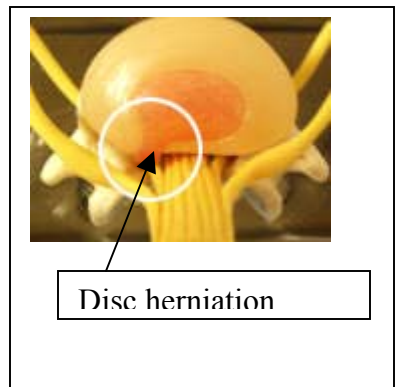
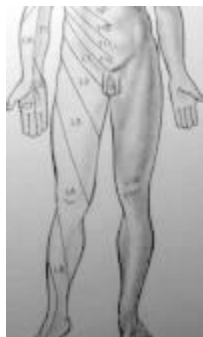

Spinal nerves (seen on left) exit the spinal canal at every level within the spine. When a herniated disk (seen below) presses upon a nerve, one experiences symptoms referable to the motor and sensory distribution of the nerve. This may amount to an area of numbness, or weakness of a motor group, or a change in the reflexes of a certain muscle



group. As seen below, the skin can be divided into dermatomes. Each patch of skin has its sensory level determined by the nerve which supplies (innervates) it.

Dermatomes



There are many processes protruding from the vertebral segments. The facet joints are held together with capsular ligaments. The spinous processes are held together by the interspinous ligaments. The transverse processes are secured by the intertransverse ligaments and membrane. There are anterior and posterior longitudinal ligaments running along the front and back of the vertebral bodies, respectively, holding the bodies together. These are then held in place by the extensive muscular network of the low back (shown on the right).